



# Management of teeth with dens invaginatus and apical periodontitis

## A case series

Sandra R. Hernández, MSc; Alejandro R. Pérez, PhD; Alessandra C. Baasch, DDS; Karen Brisson-Suárez, DDS; Débora P. Sellera, MSc; Patrícia H.P. Ferrari, PhD; Jorge C. Alberdi, DDS; Claudia M. Carreira, DDS; Susana Gomes-Azevedo, PhD; Flávio R.F. Alves, PhD; Isabela N. Rôças, PhD; José F. Siqueira, Jr., PhD

### ABSTRACT

**Background.** Dens invaginatus is a dental anomaly that can predispose the tooth to pulp and periapical pathology.

**Case Description.** Different endodontists treated 6 maxillary incisors with dens invaginatus associated with apical periodontitis. Cone-beam computed tomography was used to help with diagnosis and treatment planning in most patients. Four patients received diagnoses of Oehlers type II dens invaginatus and the other 2 as type III. In some patients with type II, the invagination had to be perforated to permit access to the apical part of the true root canal. Both the true canal and the invagination (pseudocanal) were treated in all cases using an antimicrobial regimen based on chemomechanical preparation with sodium hypochlorite irrigation and supplementary disinfection approaches. Calcium hydroxide medication was used in all but 1 case. The root canal and invagination were often filled using thermoplasticized gutta-percha techniques, sometimes using an apical plug with a bioceramic material in teeth with large apical openings. All treated patients had favorable clinical and radiographic outcomes.

**Practical Implications.** Regardless of the complex anatomic variations, common strategic therapeutic approaches were identified that might serve as recommendations for proper management of teeth with dens invaginatus and apical periodontitis. These approaches include cone-beam computed tomographic planning, aggressive disinfection using sodium hypochlorite ultrasonic or sonic activation and calcium hydroxide intracanal medication, and thermoplasticized gutta-percha obturation of both the root canal and invagination.

**Key Words.** Apical periodontitis; dens invaginatus; root canal treatment; root canal infection.

JADA 2022;153(5):470-478

<https://doi.org/10.1016/j.adaj.2021.10.009>

**D**ens invaginatus, or dens in dente, is a condition that usually looks like a tooth formed within another tooth.<sup>1</sup> This dental anomaly results from an invagination of the enamel organ to the dental papilla during odontogenesis. Before dental eruption, the invagination is filled with remnants of the dental papilla or the enamel cuticle. Once the tooth erupts, the invagination becomes open to the oral cavity and may be filled with saliva, food remnants, and bacteria.<sup>2</sup>

Dens invaginatus is one of the most common developmental dental anomalies.<sup>3</sup> Its prevalence in adult teeth varies according to the studied population and tooth type, ranging from 0.3% through 10%.<sup>3</sup> Genetic factors related to ethnicity may be the reason for differences in prevalence, and people of Asian ancestry usually have a higher frequency.<sup>4</sup> Maxillary lateral incisors are affected most frequently.<sup>5,6</sup>

Radiographically, the dens invaginatus is generally seen as a radiolucent invagination surrounded by a radiopaque area (enamel) that may be limited to the tooth crown or extend through the root. Cone-beam computed tomography (CBCT) is a valuable tool to evaluate dens invaginatus. CBCT can identify the 3-dimensional relationship with the normal tooth anatomy and the root canal and

help plan the best treatment strategy.<sup>1,7,8</sup> In axial sections, the dens invaginatus can often be seen as an invagination lined with a radiopaque enamel circle and, in many cases, partially surrounded by the true root canal, which may assume a C-shape in cross-section, as it is “pushed” by the dens invaginatus.

With this type of anomaly, the pulp is at risk of developing infection because oral bacteria can penetrate and colonize the invagination and cause destruction of the enamel lining. If the enamel is already absent, bacteria and their products can diffuse from the invagination through the dentin tubules to reach the pulp. There are also instances of the invagination communicating directly with the pulp.<sup>9-11</sup> In response to bacterial colonization of the invagination, the pulp can eventually become inflamed, necrotic, and infected.

Dens invaginatus in teeth with pulp necrosis and apical periodontitis can be challenging because both can require treatment. Several case reports and reviews of dens invaginatus have been published,<sup>3,5,8,12-17</sup> and different therapeutic considerations have been identified. It is important to understand the different morphologic and pathologic complexities to approach each case individually. We describe a series of 6 cases of dens invaginatus that were treated successfully by different clinicians with some common treatment protocols for this anomaly.

## CASE SERIES

Six patients who received a diagnosis of dens invaginatus revealed by radiographs and confirmed by CBCT (in 5 cases) are described. The pulp and periapical diagnoses were based on chief symptoms and signs, pulp and periapical tests, and radiographic and CBCT findings. Patient demographics, preoperative data, and treatment outcomes are presented in the [Table](#). All teeth were treated under local anesthesia and using rubber dam isolation. Consent for treatment was obtained from the parents of all patients included in this case series.

### Case 1

A 10-year-old patient sought treatment for a sinus tract and purulent discharge on the palatal aspect of tooth no. 10, which had a conical crown shape in mesioversion and enamel hypoplasia at the buccal aspect. CBCT revealed the extension of the invagination beyond the cementoenamel junction, consistent with Oehlers type II dens invaginatus. The tooth also exhibited incomplete apical formation and periapical radiolucency ([Figure 1](#)).

An access cavity was prepared and an ultrasonic tip was used to join the canal and the invagination ([Figure 1](#)). After root canal preparation, supplementary disinfection steps were taken using passive ultrasonic irrigation (PUI), followed by photodynamic therapy using 0.01% methylene blue. Apical root formation was completed after 3 interappointment changes of calcium hydroxide medication over 9 months. The apical part of the canal was filled with gray mineral trioxide aggregate (MTA; Angelus) and a composite resin was used to fill the most coronal portion. A 12-month follow-up examination indicated complete healing of the apical periodontitis lesion ([Figure 1](#)).

### Case 2

A 14-year-old patient underwent an evaluation of tooth no. 7. This tooth had a conical crown, and radiographic and CBCT images revealed an invagination that extended slightly beyond the cementoenamel junction into the root (Oehlers type II dens invaginatus) and a large periapical radiolucency ([Figure 2](#)).

Access was prepared through the incisal surface, attempting to bypass the invagination laterally. The invagination was perforated and incorporated in the final canal preparation shape. After root canal preparation, supplementary intracanal disinfection procedures were carried out, as in case 1. The root canal was obturated with the continuous wave of compaction technique after 1 month of being medicated with calcium hydroxide. The tooth was restored, and the 42-month radiographic follow-up indicated complete healing of the apical periodontitis lesion ([Figure 2](#)).

### Case 3

A 12-year-old patient underwent an evaluation of tooth no. 10, which had a conical crown with distoversion. Radiographic and CBCT images revealed a wide and short invagination extending

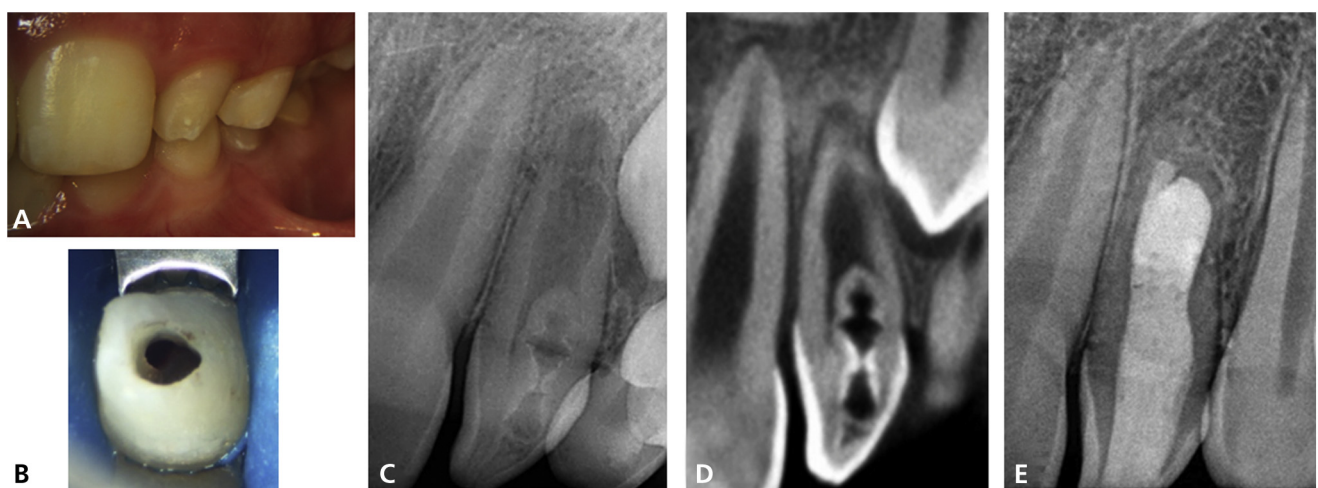
## ABBREVIATION KEY

<b>CBCT:</b>	Cone-beam computed tomography.
<b>NaOCl:</b>	Sodium hypochlorite.
<b>NSET:</b>	Nonsurgical endodontic treatment.
<b>pc:</b>	Percussion.
<b>pp:</b>	Palpation.
<b>pst:</b>	Pulp sensitivity tests.
<b>PUI:</b>	Passive ultrasonic irrigation.

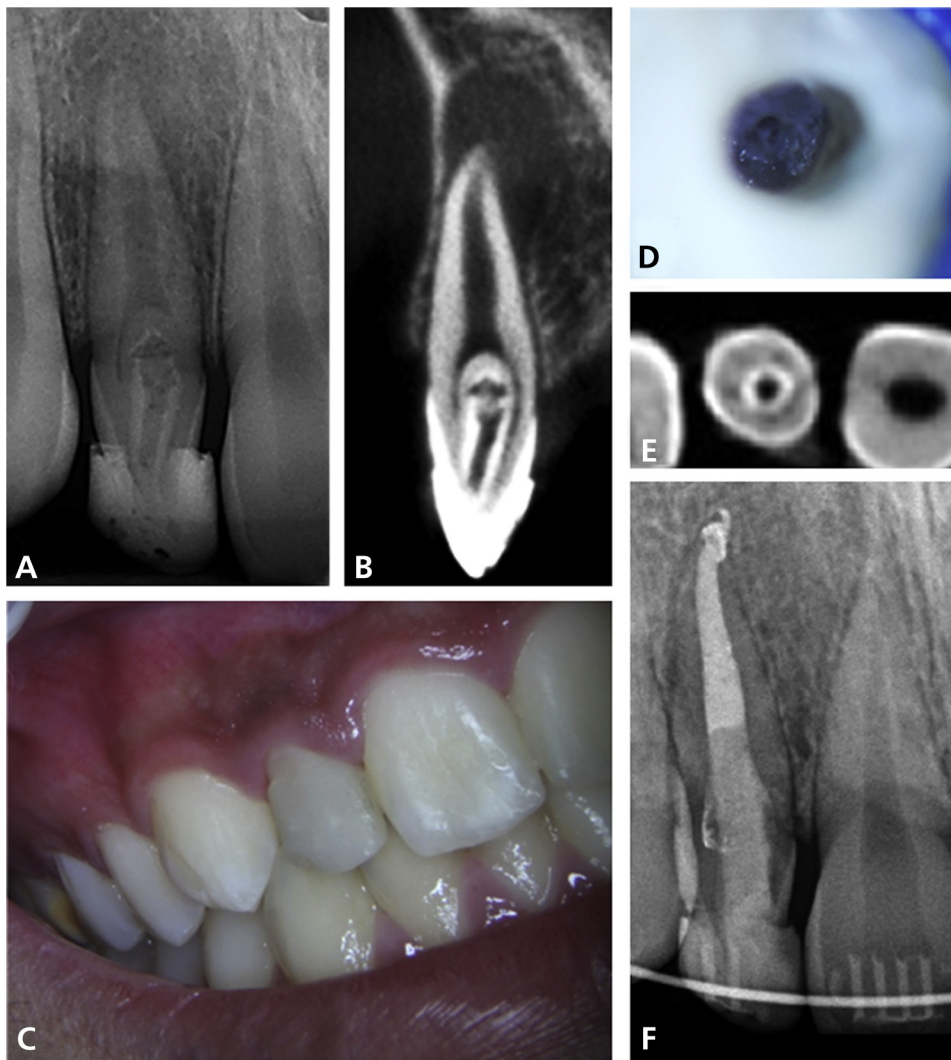
**Table.** Diagnosis and treatment outcomes of 6 teeth with dens invaginatus.

CASE NO.	SEX	AGE, Y	DENTAL HISTORY	AFFECTED TOOTH NO.	TOOTH CROWN MORPHOLOGY	OEHLERS DENS INVAGINATUS TYPE	CLINICAL TESTS	ROOT CANAL CONDITION	PERIRADICULAR DIAGNOSIS	TREATMENT	PERIRADICULAR STATUS (OUTCOME)	FOLLOW-UP, MO
1	Male	10	Sinus tract	10	Conical	II	pst*: negative pc†: negative pp‡: negative	Necrosis	Chronic apical abscess	NSET§	Healed	12
2	Male	14	Radiographic finding	7	Conical	II	pst: negative pc: positive	Necrosis	Symptomatic apical periodontitis	NSET	Healed	42
3	Female	12	Sinus tract¶	10	Conical	II	pst: negative pc: positive pp: positive	Necrosis	Asymptomatic apical periodontitis	NSET	Healing	6
4	Female	12	Radiographic finding Sinus tract	10	Normal	II	pst: negative pc: negative pp: negative	Necrosis	Chronic apical abscess	NSET	Healing	5
5	Female	13	Radiographic finding	9	Asymmetric macrodontia	III	pst: negative pc: negative	Necrosis	Asymptomatic apical periodontitis	NSET	Healed	120
6	Female	8	Acute alveolar abscess (hospital management)	7	Peg-shaped	III	pst: positive pc: positive pp: negative	Vital pulp	Asymptomatic apical periodontitis	NSET	Healing	6

\* pst: Pulp sensitivity tests. † pc: Percussion. ‡ pp: Palpation. § NSET: Nonsurgical endodontic treatment. ¶ Reported by the patient but not observed at clinical examination.



**Figure 1.** Case 1. **A.** Clinical aspect. **B.** Access cavity including both the true root canal and the invagination. **C.** Initial radiographic image. **D.** Cone-beam computed tomographic image. **E.** Radiographic image at the 12-month follow-up revealing that the apical periodontitis lesion has healed.



**Figure 2.** Case 2. **A.** Initial radiographic image. **B.** Cone-beam computed tomographic image. **C.** Clinical aspect. **D.** Access cavity including both the true root canal and the invagination. **E.** Cone-beam computed tomographic scan showing the invagination lined with enamel. **F.** Radiographic image at the 42-month follow-up, revealing that the apical periodontitis lesion has healed.

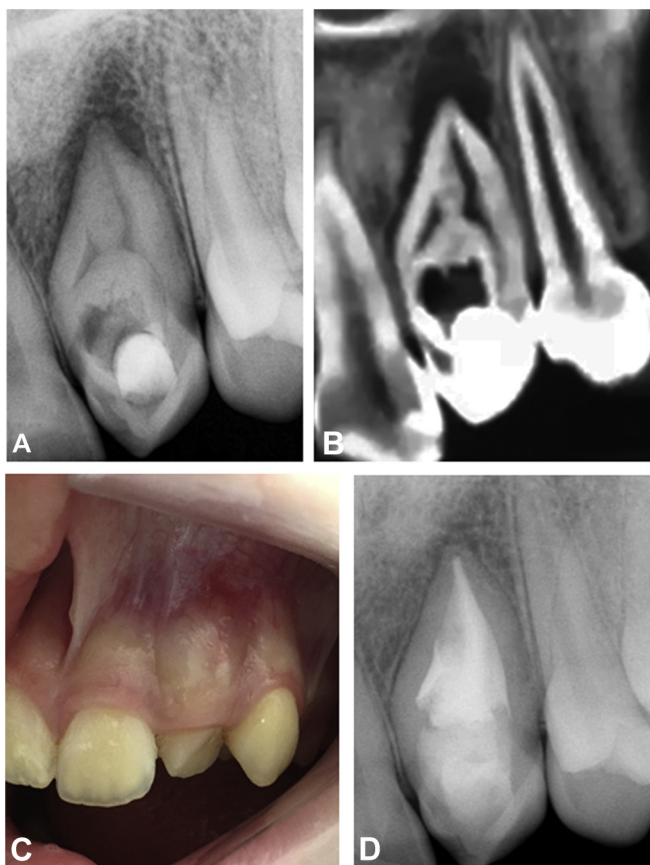
slightly beyond the cementoenamel junction (Oehlers type II dens invaginatus) (Figure 3). The tooth was associated with apical periodontitis.

In the first endodontic session, the canal was instrumented and a supplementary step with PUI was conducted before calcium hydroxide medication was applied. In the second appointment, the invagination was intentionally perforated with an ultrasonic tip, the apical canal enlarged, and calcium hydroxide applied once again. Another change of medication was performed at the third visit. The canal was obturated at the fourth visit using a thermomechanical compaction technique. The tooth was restored, and the 6-month follow-up indicated that apical periodontitis was almost completely healed (Figure 3).

#### Case 4

A 12-year-old patient sought treatment for a periapical lesion and a sinus tract associated with tooth no. 10. Radiographic and CBCT images also revealed an invagination surrounded by a radiopaque area that extended beyond the cementoenamel junction into the immature root (Oehlers type II dens invaginatus) (Figure 4).

The endodontic treatment was performed in 3 visits. Conventional access was prepared, and the terminus of the invagination was perforated intentionally with an ultrasonic tip. The apical segment of the true canal was instrumented, and then a supplementary disinfection step was conducted using



**Figure 3.** Case 3. **A.** Initial radiographic image. **B.** Cone-beam computed tomographic image. **C.** Clinical aspect. **D.** Radiographic image at the 6-month follow-up showing almost complete healing of the apical periodontitis lesion.

sodium hypochlorite (NaOCl) agitation with an XP-endo Finisher (FKG Dentaire) for 1 minute, followed by PUI with NaOCl and then 17% ethylenediaminetetraacetic acid for 1 minute each. Calcium hydroxide was used as an intracanal medication. At the next visit, a Biodentine (Septodont) plug was placed apically and the canal was filled using the single-cone technique. The final restoration was placed, and the 5-month follow-up revealed healing of the apical periodontitis lesion (Figure 4).

### Case 5

A 13-year-old patient sought treatment for tooth no. 9. Radiographs revealed a dens invaginatus displaced to the mesial aspect of the tooth parallel to the main canal. An extensive periapical radiolucency associated with both tooth no. 9 and tooth no. 10 was observed. The tooth had an asymmetric crown appearance (macrodonia) (Figure 5).

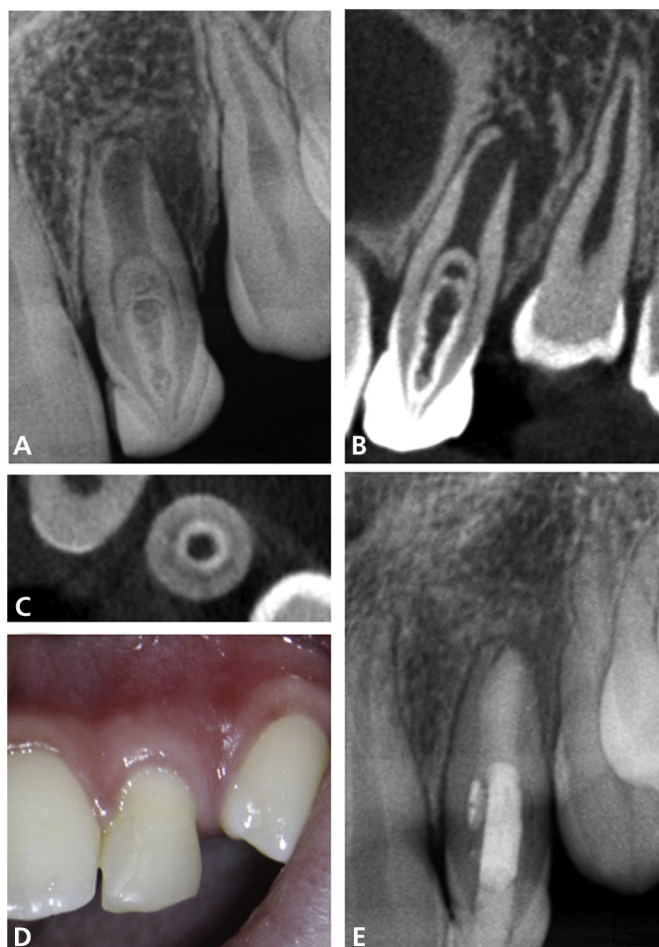
The endodontic treatment was provided in 3 visits. Access preparation was performed to include both the true canal and the invagination. Exploration of the invagination revealed an apical exit (Oehlers type III dens invaginatus). Both the true root canal and the invagination were instrumented and then medicated with calcium hydroxide for 3 months. Next, the true canal was obturated using the lateral compaction technique, and the invagination was filled with ProRoot MTA (Dentsply Sirona). The apical periodontitis lesion was healed at 10-year follow-up (Figure 5).

### Case 6

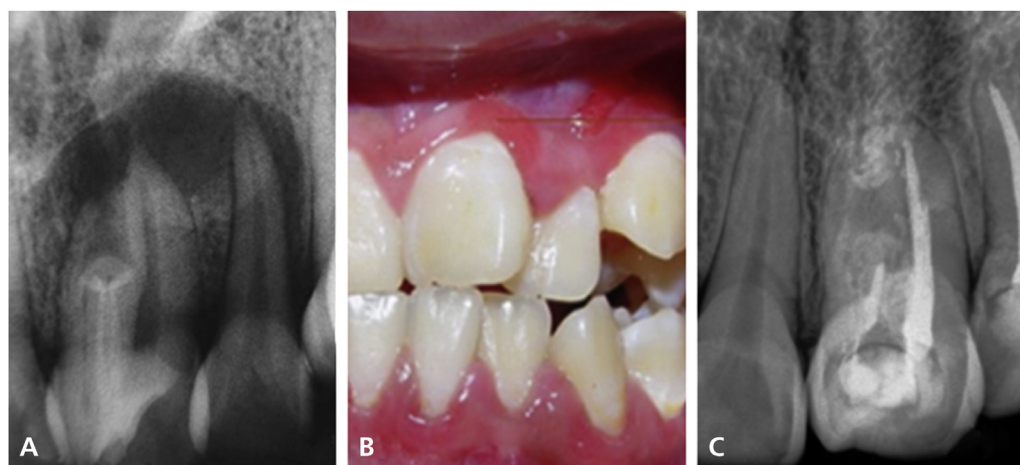
An 8-year-old patient underwent an evaluation of tooth no. 7. One week before consultation, the patient had been hospitalized because of an acute alveolar abscess, which was treated with intravenous antibiotics for 72 hours.

At consultation, the patient was asymptomatic. Intraoral examination revealed a peg-shaped tooth that responded positively to sensitivity pulp tests. An invagination was radiographically



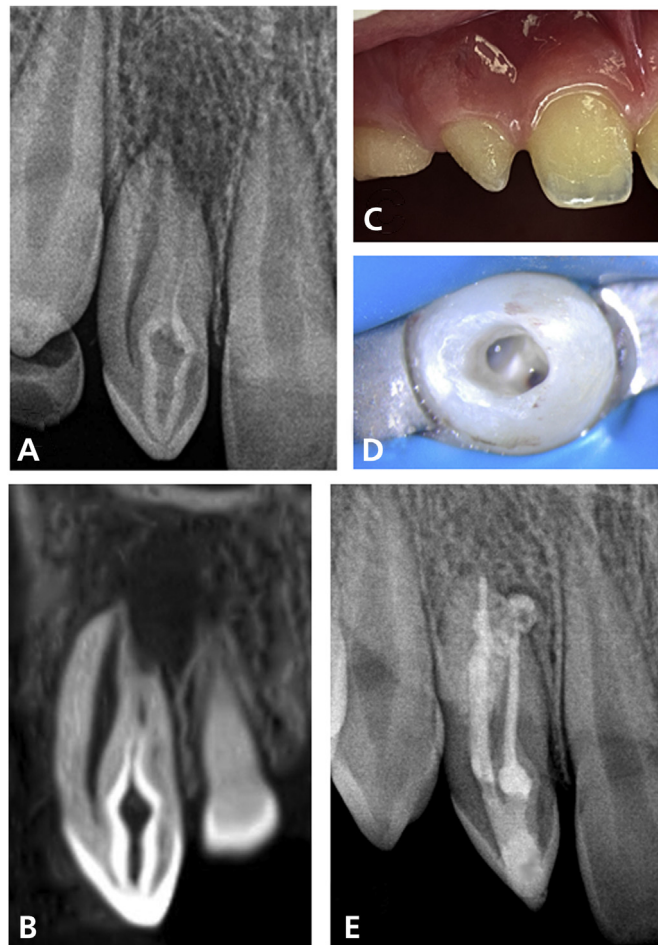


**Figure 4.** Case 4. **A.** Initial radiographic image. **B.** Cone-beam computed tomographic image. **C.** Cone-beam computed tomographic scan showing the invagination in cross-section lined with enamel. **D.** Clinical aspect. **E.** Radiographic image at the 5-month follow-up revealing that the apical periodontitis lesion was in the healing process.



**Figure 5.** Case 5. **A.** Initial radiograph. **B.** Clinical aspect. **C.** Radiographic image at the 120-month follow-up showing that the apical periodontitis lesion has healed.

detected on the mesial aspect of tooth no. 7, with the true root canal displaced to the distal side. The invagination extended beyond the cemento-enamel junction up to the coronal one-third and continued to the apex as a pseudocanal (Oehlers type III dens invaginatus). The root canal assumed



**Figure 6.** Case 6. **A.** Initial radiographic image. **B.** Cone-beam computed tomographic images. **C.** Clinical aspect. **D.** Access cavity including both the true root canal and the invagination. **E.** Radiographic image at the 6-month follow-up showing substantial reduction of the apical periodontitis lesion.

a C-shape around the invagination, which was observed on CBCT scans. Apical periodontitis was diagnosed (Figure 6).

The initial decision was to treat the invagination only, which was accessed through its opening at the palatal aspect and negotiated to its apical terminus. Bleeding occurred during instrumentation of the invagination, and the clinician suspected a communication with the true canal, exposing the vital pulp tissue. Therefore, pulpectomy was performed in the true canal, which was also treated. After preparation, a supplementary disinfection approach was conducted using agitation of NaOCl and ethylenediaminetetraacetic acid with an ultrasonic device (EndoActivator; Dentsply Sirona). The true canal was obturated using the continuous wave compaction technique and the invagination with the single-cone technique. At 6-month follow-up, the patient continued to be asymptomatic and a substantial reduction of the apical periodontitis lesion was evident (Figure 6).

## DISCUSSION

The 6 cases of dens invaginatus with pulp and periapical pathoses included 5 maxillary lateral incisors and 1 maxillary central incisor, which is consistent with the reported higher prevalence of this anomaly in lateral maxillary incisors.<sup>1,18,19</sup> Clinical inspection revealed diverse tooth crown morphologies. The opening of the invagination was always on the palatal side and usually narrow and small, which can make it difficult to detect during inspection, especially in the absence of magnification and because of bacterial plaque or food debris accumulation. In these cases, the use of an operating microscope and stains helped identify the invagination opening.

The invagination was either lateral or centered in relation to the true root canal. When it was at the center of the tooth, the true root canal assumed a C-shape surrounding most of the invagination

perimeter up to some extent in the root, as observed in CBCT axial scans and often confirmed after preparation of the access cavity.

All of the dens invaginatus cases were associated with apical periodontitis. The true canals in 5 of the 6 cases were necrotic. In cases like these, both the true canal and the invagination require treatment. Because there was no other apparent cause of pulp necrosis, bacterial colonization of the invagination was likely to be responsible for the pulp pathology leading to infection and development of periapical inflammation. Ideally, the root canal and invagination should be treated separately to avoid unnecessary removal of tooth structure. However, this is not always possible, and the operator may decide to join the canal and the invagination to establish or improve access to the apical portion of the infected canal system.

Four of the cases we reported were classified as Oehlers type II dens invaginatus and the other 2 cases were Oehlers type III dens invaginatus. Both of these types require a more complex therapeutic approach than Oehlers type I dens invaginatus and the decision-making process is not usually straightforward because there are no established treatment guidelines. In Oehlers type II dens invaginatus, the invagination ends in a blind sac and extends through the root without communicating with the periapical tissues. It should be approached as another root canal, but its internal anatomic irregularities can make it difficult to clean and disinfect properly. Oehlers type III dens invaginatus finishes at the periodontal ligament laterally (subtype IIIa) or apically (subtype IIIb). These cases are conceivably the most difficult ones to manage because bacteria colonizing the invagination have direct access to the periapical tissues to cause apical or lateral periodontitis.

One tooth with the invagination reaching the periapical tissues (Oehlers type III dens invaginatus) had a vital pulp. In this case, bacteria colonizing the invagination caused the periapical inflammation. There would be no need to treat the root canal in such cases because the pulp is vital and not infected.<sup>1,8</sup> However, during chemomechanical preparation of the invagination, a communication with the true canal containing vital pulp tissue was detected and the clinician decided to treat the root canal as well.

In 3 of the cases of Oehlers type II dens invaginatus, the C-shaped true canal surrounding the invagination was too narrow in its entire cross-section to permit successful negotiation with files to its round and larger apical segment located ahead of the dens invaginatus. This limitation required perforating the apical terminus of the invagination to access, clean, and disinfect the apical portion of the true root canal.

Proper disinfection of the complex anatomy of the invagination may require supplementary steps, such as NaOCl agitation using mechanical (for example, XP-endo Finisher or EndoActivator) or ultrasonic (PUI) means.<sup>20</sup> Photodynamic therapy was also used in 2 of our cases, although its effectiveness in enhancing root canal disinfection still needs to be supported by means of clinical studies.<sup>21</sup> Another approach to improving disinfection is intracanal medication with calcium hydroxide,<sup>22-25</sup> which was used in 5 of the 6 cases. Owing to the complex anatomy, thermoplasticized gutta-percha techniques are recommended for obturation. Occurrence of a large apical foramen associated with the true canal or invagination also required particular filling strategies, including placement of an apical plug with a biocompatible bioceramic material.

## CONCLUSIONS

The distinct anatomic features of every case of dens invagination we reported can make it difficult to establish any standardized treatment protocol. Therefore, patient-anatomy-based planning is essential for success and requires good imaging. CBCT is a valuable tool for choosing the best treatment approach.<sup>1,7,8</sup> Although different and unrelated endodontists treated the reported cases, some common approaches to successfully manage treatment of teeth with dens invaginatus were identified. These approaches can help guide the clinician to manage this unusual and difficult to treat condition. ■

---

Dr. Hernández is a member of the Endochat Research Group, Rio de Janeiro, Rio de Janeiro, Brazil, a PhD student, Postgraduate Program in Dentistry, University of Grande Rio, Rio de Janeiro, Rio de Janeiro, Brazil, and a professor, Department of Endodontics, Francisco Marroquín University, Guatemala City, Guatemala.

Dr. Pérez is a member of the Endochat Research Group, Rio de Janeiro, Rio de Janeiro, Brazil, a professor, Department of Endodontics, Rey Juan Carlos University, Madrid, Spain, and a professor, Clinical and Experimental Research Group in Materials for Dentistry and Tissue Engineering, Universidad Católica de Murcia, Murcia, Spain.



Dr. Baasch is a member of the Endochat Research Group, Rio de Janeiro, Rio de Janeiro, Brazil, a master's student, Postgraduate Program in Dentistry, University of Grande Rio, Rio de Janeiro, Rio de Janeiro, Brazil, and a professor, Department of Endodontics, Santa María University, Caracas, Venezuela.

Dr. Brisson-Suárez is a member of the Endochat Research Group, Rio de Janeiro, Rio de Janeiro, Brazil, a master's student, Postgraduate Program in Dentistry, University of Grande Rio, Rio de Janeiro, Rio de Janeiro, Brazil and a professor, Department of Endodontics, Santa María University, Caracas, Venezuela.

Dr. Sellaera is a member of the Endochat Research Group, Rio de Janeiro, Rio de Janeiro, Brazil and a clinical endodontist in private practice, Santos, São Paulo, Brazil.

Dr. Ferrari is a member of the Endochat Research Group, Rio de Janeiro, Rio de Janeiro, Brazil and a professor, specialization course, Associação Paulista de Cirurgiões-Dentistas, Santo André, São Paulo, Brazil.

Dr. Alberdi is a member of the Endochat Research Group, Rio de Janeiro, Rio de Janeiro, Brazil, a professor, Department of Endodontics, Faculty of Health Sciences, Catholic University of Córdoba, Córdoba, Argentina, and a professor, National University of Northeast, Corrientes, Argentina.

Dr. Carreira is a member of the Endochat Research Group, Rio de Janeiro, Rio de Janeiro, Brazil and a professor, Department of Clinical Dentistry, University Center FIBRA-Integrated School Brazil Amazon, Belém, Pará, Brazil.

Dr. Gomes-Azevedo is a member of the Endochat Research Group, Rio de Janeiro, Rio de Janeiro, Brazil and a clinical endodontics in private practice, Monterrey, Mexico.

Dr. Alves is a professor, Postgraduate Program in Dentistry, University of Grande Rio, Rio de Janeiro, Rio de Janeiro, Brazil and a professor, Department of Dental Research, Faculty of Dentistry, Iguazu University, Nova Iguaçu, Rio de Janeiro, Brazil. Address correspondence to Dr. Alves, Postgraduate Program in Dentistry, University of Grande Rio, Rio de Janeiro, Rua Professor José de Souza Herdy, 1160 Duque de Caxias, Rio de Janeiro, Brazil 25071-202, email [flavioferreiraalves@gmail.com](mailto:flavioferreiraalves@gmail.com).

Dr. Rôças is a member of the Endochat Research Group, Rio de Janeiro, Rio de Janeiro, Brazil, a professor, Postgraduate Program in Dentistry, University of Grande Rio, Rio de Janeiro, Rio de Janeiro, Brazil and professor, Department of Dental Research, Faculty of Dentistry, Iguazu University, Nova Iguaçu, Rio de Janeiro, Brazil.

Dr. Siqueira is a member of the Endochat Research Group, Rio de Janeiro, Rio de Janeiro, Brazil, a professor, Postgraduate Program in Dentistry, University of Grande Rio, Rio de Janeiro, Rio de Janeiro, Brazil, and professor, Department of Dental Research, Faculty of Dentistry, Iguazu University, Nova Iguaçu, Rio de Janeiro, Brazil.

**Disclosure.** None of the authors reported any disclosures.

1. Rotstein I, Llamas E, Choi K-S. Endodontic therapy in teeth with anatomical variations. In: Rotstein I, Ingle JI, eds. *Ingle's Endodontics*. 7th ed., PMPH USA; 2019:866-869.

2. Kronfeld R. Dens in dente. *J Dent Res*. 1934;14(1):49-66.

3. Alani A, Bishop K. Dens invaginatus, part 1: classification, prevalence and aetiology. *Int Endod J*. 2008;41(12):1123-1136.

4. Levitan ME, Himel VT. Dens evaginatus: literature review, pathophysiology, and comprehensive treatment regimen. *J Endod*. 2006;32(1):1-9.

5. Hulsmann M. Dens invaginatus: aetiology, classification, prevalence, diagnosis, and treatment considerations. *Int Endod J*. 1997;30(2):79-90.

6. Cakici F, Celikoglu M, Arslan H, Topcuoglu HS, Erdogan AS. Assessment of the prevalence and characteristics of dens invaginatus in a sample of Turkish Anatolian population. *Med Oral Patol Oral Cir Bucal*. 2010;15(6):e855-e858.

7. Vier-Pelisser FV, Pelisser A, Recuero LC, Só MVR, Borba MG, Figueiredo JAP. Use of cone beam computed tomography in the diagnosis, planning and follow up of a type III dens invaginatus case. *Int Endod J*. 2012;45(2):198-208.

8. Patel S. The use of cone beam computed tomography in the conservative management of dens invaginatus: a case report. *Int Endod J*. 2010;43(8):707-713.

9. Oehlers FA. Dens invaginatus (dilated composite odontome), I: variations of the invagination process and

associated anterior crown forms. *Oral Surg Oral Med Oral Pathol*. 1957;10(11):1204-1218.

10. Rushton MA. Invaginated teeth (dens in dente): contents of the invagination. *Oral Surg Oral Med Oral Pathol*. 1958;11(12):1378-1387.

11. Ricucci D, Milovidova I, Siqueira JF Jr. Unusual location of dens invaginatus causing a difficult-to-diagnose pulpal involvement. *J Endod*. 2020;46(10):1522-1529.

12. Kumar H, Al-Ali M, Parashos P, Manton DJ. Management of 2 teeth diagnosed with dens invaginatus with regenerative endodontics and apexification in the same patient: a case report and review. *J Endod*. 2014;40(5):725-731.

13. Meghana SM, Thejokrishna P. Type III dens invaginatus with an associated cyst: a case report and literature review. *Int J Clin Pediatr Dent*. 2011;4(2):139-141.

14. Bishop K, Alani A. Dens invaginatus, part 2: clinical, radiographic features and management options. *Int Endod J*. 2008;41(12):1137-1154.

15. Mupparapu M, Singer SR. A review of dens invaginatus (dens in dente) in permanent and primary teeth: report of a case in a microdontic maxillary lateral incisor. *Quintessence Int*. 2006;37(2):125-129.

16. Fregnani ER, Spinola LF, Sonog JR, Bueno CE, De Martin AS. Complex endodontic treatment of an immature type III dens invaginatus: a case report. *Int Endod J*. 2008;41(10):913-919.

17. Sathorn C, Parashos P. Contemporary treatment of class II dens invaginatus. *Int Endod J*. 2007;40(4):308-316.

18. Kirzioglu Z, Ceyhan D. The prevalence of anterior teeth with dens invaginatus in the western Mediterranean region of Turkey. *Int Endod J*. 2009;42(8):727-734.

19. Hovland EJ, Block RM. Nonrecognition and subsequent endodontic treatment of dens invaginatus. *J Endod*. 1977;3(9):360-362.

20. Siqueira JF Jr., Rôças IN. Optimising single-visit disinfection with supplementary approaches: a quest for predictability. *Aust Endod J*. 2011;37(3):92-98.

21. Chrepa V, Kotsakis GA, Pagonis TC, Hargreaves KM. The effect of photodynamic therapy in root canal disinfection: a systematic review. *J Endod*. 2014;40(7):891-898.

22. Paiva SS, Siqueira JF Jr., Rôças IN, et al. Clinical antimicrobial efficacy of NiTi rotary instrumentation with NaOCl irrigation, final rinse with chlorhexidine and interappointment medication: a molecular study. *Int Endod J*. 2013;46(3):225-233.

23. Shuping GB, Orstavik D, Sigurdsson A, Trope M. Reduction of intracanal bacteria using nickel-titanium rotary instrumentation and various medications. *J Endod*. 2000;26(12):751-755.

24. Huffaker SK, Safavi K, Spångberg LS, Kaufman B. Influence of a passive sonic irrigation system on the elimination of bacteria from root canal systems: a clinical study. *J Endod*. 2010;36(8):1315-1318.

25. Vera J, Siqueira JF Jr., Ricucci D, et al. One- versus two-visit endodontic treatment of teeth with apical periodontitis: a histobacteriologic study. *J Endod*. 2012;38(8):1040-1052.